

# Benign Sinonasal Masses: A Clinicopathological and Radiological Profile

Nepal A,<sup>1</sup> Chettri ST,<sup>2</sup> Joshi RR,<sup>2</sup> Karki S<sup>3</sup>

<sup>1</sup>Department of Otolaryngology and Head Neck Surgery

Patan Academy of Health Sciences

Lagankhel, Nepal

<sup>2</sup>Department of Otolaryngology

<sup>3</sup>Department of Pathology

B. P. Koirala Institute of Health Sciences

Dharan, Nepal

## Corresponding Author

Ajit Nepal

Department of Otolaryngology and Head Neck Surgery

Patan Academy of Health Sciences

Lagankhel, Nepal

E-mail: ajitnepal2001@yahoo.com

## Citation

Nepal A, Chettri ST, Joshi RR, Karki S. Benign Sinonasal Masses: A Clinicopathological and Radiological Profile. *Kathmandu Univ Med J* 2013;41(1):4-8.

## ABSTRACT

### Background

Benign nasal and paranasal sinus masses are commonly encountered in clinical practice. Though benign, certain nasal polyps, fungal sinusitis, hemangiomas and fibro-osseous tumors can present with locally destructive features and deformities, mimicking malignancies at once.

### Objective

This study was carried out to recognize the great variety of benign nasal lesions and their frequency in our region.

### Methods

A retrospective chart analysis of cases presenting as mass in nose and paranasal sinus that underwent surgery over three years duration at our institute was done. A provisional diagnosis was made after clinical assessment and radiological investigations, but the final diagnosis was established after histopathological examination.

### Results

A total 331 cases presented as masses in nose and paranasal sinus presented during the period. The clinicopathological examination aided by endoscopic and imaging studies revealed the non neoplastic benign masses in 293 and neoplastic masses in 38. Polyps were the commonest lesions constituting 70% cases followed by rhinosporidiosis in 10%. Fungal sinusitis, squamous papillomas, hemangiomas and inverted papillomas were found to be in order of 4.5%, 4%, 3.5% and 3% respectively. Rare cases like "rhino-oto-cerebral" form of mucormycosis, angiomatoma, and psammomatoid ossifying fibroma were also observed in the study.

### Conclusion

Most of the nasal polyps/fungal sinusitis can be diagnosed clinically. However many a times Computer tomography (CT) scan and biopsy are necessary to differentiate them from each other and treatment plan. Certain benign tumors have high potential for malignant transformation while others can present with locally destructive features and deformities.

## KEY WORDS

*Angiomatoma, benign, fungal, polyps, rhinosporidiosis, sinonasal*

## INTRODUCTION

Benign nose and para nasal sinus masses, either neoplastic or non-neoplastic are commonly encountered in clinical practice. A large number of diseases affecting the region are mainly due to several specialized tissues in the region and their aberrations.<sup>1</sup> Few may be infective in origin. Careful clinicopathological workup aided by various imaging is essential for a correct diagnosis and timely intervention

and to lessen the morbidity to the patient. Nasal papillomas are potential malignant tumors and timely diagnosis and surgery can prevent them from malignant transformation.<sup>2</sup> This study was carried out to recognize the great variety of benign nasal lesions, their character and frequency in our region.

## METHODS

This is a descriptive retrospective study carried out in the department of Otolaryngology, B. P. Koirala Institute of Health Sciences, Dharan, Nepal between April 2005 and March 2008 including 331 cases of benign sinonasal masses. The study was approved by the ethical committee of the institution. All cases had been first evaluated clinically and nasal endoscopy and imaging studies were done wherever applicable. Histopathological examinations were done in all cases postoperatively and in selective cases preoperatively to ascertain diagnosis. All the malignant cases and medically treated cases were excluded from the study. Detail of types of lesions, symptoms, duration of presentation, clinical, radiological and histopathological findings were recorded and data was analyzed using Microsoft Excel 2003.

## RESULTS

Total 331 cases of sinonasal masses in Nose and PNS with 293 benign non-neoplastic and 38 neoplastic in nature was found. Nasal polyps were the commonest lesions observed (70%), with ethmoidal polyps outnumbering antrochoanal (AC) polyps. Second most common pathology was rhinosporidiosis (10%). Fungal sinusitis, squamous papillomas, hemangiomas and inverted papillomas were found in 4.5%, 4%, 3.5% and 3% respectively. The incidence of non-neoplastic masses of nasal cavity (NC), PNS, and nasopharynx (NP) was 87% out of which 15% were infective in origin (Table 1). Only 13% cases were benign neoplastic masses. Age of presentation ranged from 1st to 8th decade of life with highest incidence in age group 16-30 years (44%) with 80% falling under 45 years. Average duration during presentation was nine months. The male to female ratio was 3:2.

Nose blocking and nasal discharge were the commonest symptoms overall followed by itching, sneezing, headache, nose bleeding etc. (Fig. 1).

NC and PNS were involved in 78.5% of the cases with 23% cases extending to NP. 20 % cases (mostly rhinosporidiosis and squamous papillomas and some hemangiomas) had involvement of nasal cavity alone. 1.5% cases

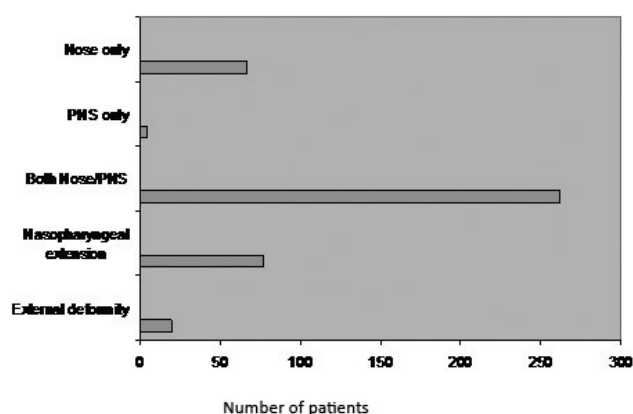


Figure 1. Symptoms of the patients.

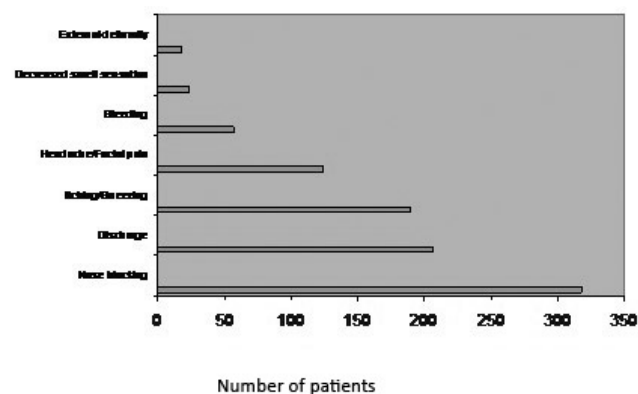


Figure 2. Sites of involvement.

Table 1. Distribution of cases (Total 331 cases).

Non Neoplastic Masses			Neoplastic Masses		
Infective	No.	Non Infective	No.	Neoplastic	No.
Rhinosporidiosis	33	Ethmoid Polyps	130	Squamous Papilloma	12
Fungal Sinusitis	14	AC Polyp	103	Hemangioma	11
Rhinocleroma	2	NL Cyst	4	Inverted Papilloma	9
		Dermoid Cyst	2	Osteoma	2
		FE Mucocele	2	Fibrous Dysplasia	1
		W. Granulomatosis	1	Ossifying Fibroma	1
		Dentigerous Cyst	1	Pleomorphic Adenoma	1
		Rhinolith	1	Angiomyoma	1
			49 (15%)		38 (11%)

Table 2. Investigations.

Diagnosis	CT Scan	Biopsy
Ethmoidal Polyps(130)	130	14
AC Polyp(103)	32	3
Rhinosporidiosis (33)	8	8
Fungal Sinusitis(14)	14	14
Sq. Papilloma(12)	0	2
Hemangioma(11)	3	1
Inverted Papilloma(9)	9	9
NL Cyst(4)	1	1
Others(15)	11	7
Total(331)	208(63%)	59(18%)

comprising fibro-osseous tumors, dentigerous cysts, and frontoethmoidal mucocele involved the PNS only. Six percent of cases (ethmoidal polyps, fungal sinusitis, nasolabial cysts, frontoethmoidal mucocele and osteomas) caused external deformities like fullness of cheek, splaying of nasal bones and proptosis (Fig. 2).

Out of all cases in 63% of the cases CT scan was done and in

18% of the cases pre-operative biopsy was done. However diagnosis was confirmed in all the cases post operatively (Table 2).

Nasal polyps were the most common lesion involving this region. The age range was from seven years to 79 years, with peak seen in the 3<sup>rd</sup> and 4<sup>th</sup> decade. Ninety eight percent of ethmoidal polyps and 2% cases of antrochoanal polyps were bilateral. All patients presented with symptoms of nasal stuffiness and obstruction. Other symptoms were alteration of smell, headache, sneezing, and discharge. On examination, the mass was pale, glistening grape-like, insensitive to probing and did not bleed on touch. Microscopically, the polyps were composed of loose mucoid stroma infiltrated by lymphocytes, plasma cells, neutrophils with the mucus glands covered by respiratory epithelium.

Rhinosporidiosis were four times common in males and three quarter of the patients were in 2<sup>nd</sup> to 4<sup>th</sup> decade of life. Over 90% of the cases found in our study were from Saptari alone with majority of Indo-Aryan origin who shared the same pond with that for cattle. Nasal blockage, irritation and epistaxis were the common modes of presentation. Friable, polypoidal, reddish strawberry like mass in the nasal cavity studded with grayish dots of sporangia were the commonest finding. The lesions were sensitive and bled to touch. In 80% of the cases, it was confined to the nasal cavity, in 17%, there was extension to nasopharynx and in 3% to maxillary sinus. Two cases had their extension upto oropharynx. Total 17% had bilateral disease and 7% had extensive disease filling the nasal cavities. Sixty five percent of the cases were single and pedunculated with the remaining either multiple or sessile. Diagnosis was mostly clinical. Histology showed vascular fibromyxomatous structure with submucosal sporangia containing innumerable endospores seen by H and E stain with plasma cells and eosinophils around the chronic inflammatory response.

Over 90% patients of fungal sinusitis were in third to fifth decade of life with male-to-female ratio of 1.5:1. They presented with nose blockage, thick foul smelling nasal discharge and itching. CT PNS showed foci of typical calcification and heterogenous attenuation. There were evidences of bone erosion in invasive mucormycosis and in one case; it was seen encroaching intracranially through the left orbit after eroding the cribriform plate, lamina paparaecia and roof of sphenoid sinus. The culture was positive on Sabouraud's dextrose agar medium and histopathology of 11 cases showed allergic fungal sinusitis due to *A. fumigatus* and three cases showed chronic invasive mucormycosis.

Among papillomas, nine were cases of inverted papilloma, of those only one was female. All cases were from 4<sup>th</sup> - 6<sup>th</sup> decade except the female who was 29-year old. All cases presented with unilateral nasal obstruction followed by nasal discharge (44%), epistaxis (33%) headache (33%),

and facial numbness/fullness (22%). CT scan was done in all cases with most showing bowing of the medial wall of maxilla with local bony destruction surrounding the soft tissue mass. There was no side predilection. 66% of the cases were limited to maxillary and ethmoid sinuses and in 22% cases, there was extension to cheek anteriorly causing splaying of nasal bone and involvement of sphenoid. One case had limited to middle meatus and anterior ethmoid region only. All the squamous papilloma type had their origin from nasal vestibule area and ranged 1-3 cm in size.

There were 11 cases of hemangiomas. Four of them were arteriovenous (AV) malformations and pyogenic granulomas (lobular capillary hemangiomas) each and three were cavernous hemangiomas. Cavernous hemangiomas were found in elderly males while pyogenic granulomas and AV malformations were prevalent in adolescents and young adults. All cases presented with unilateral nasal obstruction. Recurrent epistaxis was present in five cases and two had hemifacial pain. Regarding cavernous hemangiomas, one had its extension to anterior ethmoid, another to maxillary sinus and one was limited to nasal cavity with destruction of turbinates. Contrast CT confirmed the diagnosis in these cases. Other angiomatous growths (largest 2.5 cm) arising from septum were diagnosed on clinical basis and endoscopic examination.

All rhinosporidiosis, angiomyoma and Wagener's granulomatosis and few cases of inverted papilloma and hemangiomas had history of epistaxis at some time. We observed an extremely rare case of angiomyoma (vascular leiomyoma) in a 45-year female who presented with nasal obstruction and recurrent epistaxis of one year duration. Contrast CT showed a right sided, enhanced homogenous mass in all sinuses extending to opposite nasal, maxilla and anterior ethmoid with erosion of cartilaginous septum. Histopathological examination showed mature, well-differentiated smooth muscle cells mixed with thick-walled vessels.

Two of the rhinoscleroma and one case of Wagener's granulomatosis were observed during the study.

Cystic masses comprised of nasolabial cyst, dermoid cysts, frontoethmoid mucocele and dentigerous cysts.

Among fibro-osseous tumors, two cases of osteomas (one each frontal and maxillary) and one each of psammomatoid ossifying fibroma and fibrous dysplasias were encountered in the study.

## DISCUSSION

It is important to recognize non neoplastic and neoplastic benign lesions from malignant ones because of different treatment modality and to lessen economical burden to the patient.<sup>2</sup> All the nasal polyps removed surgically should be submitted for histopathological examinations as both benign tumors such as inverted papilloma and malignant

tumor like mucinous adenocarcinoma can mimic or coexist with "ordinary" nasal polyps.<sup>2</sup>

The incidence of nasal polyps was 70.39% in our study which was comparable to other similar studies.<sup>3-5</sup> The peak age of presentation, sex ratio, and clinical presentation were similar to that observed by these authors.

CT scan with coronal cuts is preferable prior to surgery and indeed mandatory if endoscopic sinus surgery is to be performed. The scan will show the anatomic variations including any alterations brought by the disease or by previous surgery. However in cases of extensive diseases, suspicion of fungal disease, neoplasms, encephaloceles or if optic nerves or carotid arteries are to be defined in relation to sinuses axial cuts are necessary.<sup>2</sup>

Recurrence of nasal polyps in our series was nine percent which is lower than the study by Drake-Lee et al who reported a recurrence rate of five percent and implicated several factors like younger age, long history and association with asthma and aspirin hypersensitivity for the recurrence.<sup>5</sup>

Fungal rhinosinusitis, once considered a rare disorder, has been reported with increasing frequency worldwide over the last 2-3 decades.<sup>6,7</sup> In this study, out of 14 cases of fungal sinusitis only three (21%) were invasive mucormycosis, rest being allergic fungal rhinosinusitis (AFRS). All AFRS were due *Aspergillus* species and mucin in the specimen which is important in diagnosis was present in all cases.<sup>7</sup>

Ponikau et al, in their initial study using a sensitive detection method (nasal lavage), demonstrated that 93% of patients with CRS had fungi present in tissue specimens.<sup>8</sup> However, they also identified fungus in the nasal lavage from 100% of healthy volunteers, demonstrating the ubiquitous nature of these saprophytic fungi. Thus it would be better to include demonstration of fungal element in tissue histopathologic samples in diagnostic criteria rather than culture isolation.<sup>7</sup> The noninvasive and invasive forms of fungal rhinosinusitis are not necessarily discrete and may coexist in the same patient with well-documented reports of histologic invasion in cases of AFRS.<sup>9,10</sup> In our study, three cases of *Aspergillus* had histologic evidence of invasion as well as extensive pansinus involvement in CT scan with bony erosions.

Rhinocerebral mucormycosis is a rare invasive fungal infection, with potentially fulminant course most commonly associated with diabetic ketoacidosis, hematologic malignancies, acquired immunodeficiency syndrome, and immunosuppressive therapy.<sup>11</sup> It is considered to be the most fatal fungal infection known to man because it is rapidly disseminated by the blood vessels. The clinical manifestations of the rhinocerebral form start as sinusitis, rapidly progressing to involve neighboring tissues like the orbit, eye and optic nerve and extend to the brain. Facial edema, pain, necrosis, loss of vision, black discharge along the nasal cavity angle of the eye and proptosis are usual features.

Rhinosporidiosis occurs universally, although it is endemic in south Asia, notably southern India and in Sri Lanka. Increased migration to the west of persons who acquired rhinosporidiosis in their native Asian countries has resulted in the increasing occurrence of this disease in the West.<sup>12</sup> Eastern Nepal Terai belt especially Saptari district has been emerging as the endemic zone over recent years as shown in our study. The most common presumed mode of infection from the natural aquatic habitat of *R. seeberi* is through the breached nasal mucosa.<sup>12-14</sup> Though in most instances rhinosporidiosis can be diagnosed clinically, definitive diagnosis is by histopathology on biopsied or resected tissues, with the identification of the sporangia in its diverse stages, rather than the stromal and cellular responses of the host.<sup>12</sup> In our study all tissues sent for histopathological examination were positive for the disease.

Inverted papilloma is characterized best by its predilection for males, local invasion, tendency for recurrence and association with malignancy.<sup>15</sup> In his analysis of 30 years of published reports, Krause documents the finding of carcinoma in 9.1% of all patients.<sup>16</sup> One case in our study had the histologic feature of malignant transformation. In our study, side ratio was 5:4 (more on right side) and all cases were unilateral which contrasts with Krause who noted 4.9% cases having bilateral disease. All our cases had unilateral nasal obstruction followed by nasal discharge (44%), epistaxis (33%) headache (33%), and facial numbness/fullness (22%) which is similar to those of Weissler et al except that there was unilateral nasal obstruction in only 58% of their cases.<sup>17</sup> CT scan was done in all cases, most showing the bowing of medial wall with bony erosion at places as was shown in other studies.<sup>15,18</sup>

Out of 11 squamous (epithelial) papilloma arising from nasal vestibule region, only two cases were biopsied preoperatively due to their suspicious look. In all remaining cases, excision biopsy was done. All turned out to be squamous papilloma subsequently. Abraham et al in their series of 17 cases of intranasal epithelial papillomas found that 13 were epithelial papillomas and four were squamous cell carcinomas associated with epithelial papillomas suggesting that squamous cell carcinoma may occasionally arise from a previously benign epithelial papilloma.<sup>19</sup> Five cases of our cases who were on follow up till one year have not shown any sign of regrowth.

Sinonasal hemangiomas are uncommon in literature.<sup>20,21</sup> In our study, three cases were cavernous hemangiomas, rest being minor arteriovenous malformations and pyogenic granulomas (lobular capillary hemangiomas). All the cases of cavernous hemangiomas in our study were elderly males and rest being adolescents and young adults.

Osteoma is the most common benign fibro-osseous sinonasal tumor. We encountered two osteomas, one each arising from frontal and maxillary sinus, both presented with facial pain/headache and local swelling. We also came



across a rare case of psammomatoid ossifying fibroma of frontoethmoid region in a seven year old boy who presented with headache and proptosis for one year.<sup>22</sup> His vision was normal. CT scan was suggestive of left frontal sinus mucocele with fibro osseous lesion in the same side frontoethmoid region. There was also one case of fibrous dysplasia arising from frontal sinus presenting with local swelling. Among granulomatous diseases, we observed two cases of Wagner's granulomatosis and one case of rhinoscleroma. One case of Wagner's granulomatosis presented with palatal perforation and the rhinoscleroma in stage of cicatrisation with almost complete stenosis of a nasal cavity.

We observed an extremely rare case of angiomyoma (vascular leiomyoma) in a 45-year female who presented with nasal obstruction and recurrent epistaxis of one year duration. Angiomyoma is an uncommon, benign tumor, which usually occurs on the extremities, especially the lower extremities. Occurrence in the nasal cavity is extremely rare and has rarely been described in the literature.<sup>23,24</sup>

## CONCLUSION

Most of the nasal polyps/fungal sinusitis can be diagnosed clinically. However many a times CT scan and biopsy are necessary to differentiate them from each other and for treatment planning. Eastern Nepal Terai belt especially Saptari district has been emerging as the endemic zone for rhinosporidiosis over recent years. Virtually all the rhinosporidiosis present with frequent epistaxis, often leading patients think of malignancy and impending death. Spot diagnosis and reassurance about its complete curability gives instant sigh of relief to the patient. So is the case in other benign conditions presenting with nasal bleeding. Inverted papillomas are potential malignant tumors and timely diagnosis and surgery can prevent them from malignant transformation. Though benign, certain nasal polyps, fungal sinusitis, hemangiomas and fibro-osseous tumors can present with locally destructive features and deformities mimicking malignancies at once. Thus, careful clinical workups aided by radiological and histopathological examination in selected cases are keys to correct diagnosis and timely intervention.

## REFERENCES

1. Mills SE, Fechner RE. The nose, paranasal sinuses and nasopharynx. Diagnostic Surgical Pathology. In: Sternberg SS. editor. 3rd ed. Philadelphia: Lippincott Williams & Wilkins; 1999. p. 885-92.
2. Lund VJ. Diagnosis and treatment of nasal polyps. *BMJ* 1995;311:1411-4.
3. Zafar U, Khan N, Afroz N, Hasan SA. Clinicopathological study of non-neoplastic lesions of nasal cavity and paranasal sinuses. *Indian J Pathol Microbiol* 2008;11(51):26-9.
4. Dasgupta A, Ghosh RN, Mukherjee C. Nasal polyps - Histopathologic spectrum. *Indian J Otolaryngol & Head Neck Surg* 1997;49:32-6.
5. Drake-Lee AB, Lowe D, Swamston A, Grace A. Clinical profile and recurrence of nasal polyps. *J Laryngol Otol* 1984;98:783-93.
6. Ferreiro JA, Carlson BA, Lody DT. Paranasal sinus fungal balls. *Head Neck* 1997;19:481-6.
7. Saravanan K, Panda NK, Chakrabarti A, Das A, Bapuraj RJ. Allergic Fungal Rhinosinusitis. *Arch Otolaryngol Head Neck Surg* 2006;132:173-8.
8. Ponikau JU, Sherris DA, Kern EB. The diagnosis and incidence of allergic fungal sinusitis. *Mayo Clin Proc* 1999;74:877-84.
9. Schubert MS, Goetz DW. Evaluation and treatment of allergic fungal sinusitis: demographics and diagnosis. *J Allergy Clin Immunol* 1998;102:387-94.
10. Thakar A, Sarkar C, Dhiwakar M, Bahadur S, Dahiya S. Allergic fungal sinusitis: expanding the clinicopathologic spectrum. *Otolaryngol Head Neck Surg* 2004;130:209-16.
11. DeShazo RD, O'Brien M, Chapin K, Soto-Aquilar M, Gardner L, Swain R. A new classification and diagnostic criteria for invasive fungal sinusitis. *Arch Otolaryngol Head Neck Surg* 1997;123:1181-8.
12. Arseculeratne SN. Recent advances in rhinosporidiosis and rhinosporidium seeberi. *Indian J Med Microbiol* 2002;20:119-31.
13. Kameswaran S, Lakshmanan M. Rhinosporidiosis. ENT disorders in a tropical environment. In: Kameswaran S, Kameswaran M, editor. Chennai: MERF Publications; 1999. p. 19-34.
14. Sudarshan V, Goel NK, Gahine R, Krishnani C. Rhinosporidiosis in Raipur, Chhattisgarh: a report of 462 cases. *Indian J Pathol Microbiol* 2007 Oct;50(4):718-21.
15. Christopher TM, Brent AS. Benign Sinonasal Neoplasms: A Focus on Inverting Papilloma. *Otol CI N Am* 2006;39:601-17.
16. Krause JH. Endoscopic treatment of inverted papilloma: safety and efficacy. *Am J Otolaryngol* 2001;22:87-99.
17. Weissler MC, Montgomery WW, Montgomery SK. Inverted papilloma. *Ann Otol Rhinolol Laryngol* 1986;95:215-21.
18. Som PM, Lawson W, Lidov MW. Simulated aggressive skull base erosion in response to benign sinonasal disease. *Radiology* 1991;180:155-9.
19. Abraham L, Philip RR, Robert SS. Epithelial papilloma and squamous cell carcinoma of the nasal cavity and paranasal sinuses- A clinicopathological study. *Cancer* 1976;38:2503-2510.
20. Jammal H, Barakat F, Hadi U. Maxillary cavernous hemangioma: a rare entity. *Acta Otolaryngol* 2004;124:331-3.
21. Iwata N, Hattori K, Nakagawa T, Tsujimura T. Hemangioma of the nasal cavity: A clinicopathologic study. *Auris Nasus Larynx* 2002;29:335-9.
22. Singh I, Ghimire A, Bhadani P, Nepal A, Maharjan M, Gauum D, et al. Proptosis in a young Child. *Ind J Paed* 2006;73:537-38.
23. Hashimoto H, Quade B. Angioleiomyoma. In: Fletcher CDM, Unni K, Mertens F. WHO classification of tumors. Pathology and genetics of tumors of soft tissue tumors. Lyon: IARC Press; 2002. p.128-9.
24. Choi JH, Kim JM, Kim YD. Angioleiomyoma of the Nasal Septum: A Case Report. *Yeungnam Univ J of Med* 2008;25:154-9.