

Ultrastructure of Chondrocytes in Osteoarthritic Femoral Articular Cartilage

Goyal N,¹ Gupta M,² Joshi K³

¹Department of Anatomy

Christian Medical College

Ludhiana, India

²Department of Anatomy

Swami Devi Dayal Dental College and Hospital

Golpura, Barwala

³Department of Histopathology

Postgraduate Institute of Medical Education

and Research, Chandigarh, India

Corresponding author

Neeru Goyal

Department of Anatomy,

Christian Medical College

Ludhiana, India

Email: meetneeru24@yahoo.co.in

Citation

Goyal N, Gupta M, Joshi K. Ultrastructure of Chondrocytes in Osteoarthritic Femoral Articular Cartilage. *Kathmandu Univ Med J* 2013;43(3):221-225.

ABSTRACT

Background

Osteoarthritis (OA) is a common problem in elderly, but it is not an inevitable feature of ageing. About 80-90% of individuals of both sexes have radiographic evidence of OA by the time they reach an age of 65. But not all of them have the symptoms like pain and decreased joint motion.

Objective

The objective of the present study was conducted to find out whether the osteoarthritic changes in human articular cartilage are similar to the ageing process or not.

Methods

Femoral articular cartilage specimens obtained from 13 osteoarthritic patients (52-80years) undergoing total knee replacement and 9 cadavers of same age group (50-80years) (control) were processed and studied under electron microscope. The ultrastructure of the cartilage from the two groups was compared with each other.

Results

Under the electron microscope, articular cartilage from control group had chondrocytes having a secretory cell characteristic with prominent nucleus and well developed organelles. In osteoarthritic cartilage, degenerating or necrotic chondrocytes were found. Nuclei of these chondrocytes appeared lobulated or indented. Chondrocytes below the fibrillated surface had dilated and irregular endoplasmic reticulum. Electron dense lipid deposits in the extracellular matrix as well as intracytoplasmic glycogen deposits were much increased in osteoarthritic cartilage as compared to the control group. Amount of perinuclear intracytoplasmic fine filaments was also increased in the chondrocytes of osteoarthritic cartilage.

Conclusion

Ultrastructural findings of the osteoarthritic articular cartilage were much different from the ageing non-osteoarthritic cartilage. Hence, OA should be considered a specific process and not simply an inevitable feature of ageing.

KEY WORDS

Chondrocyte, fibrillation, necrotic cells, osteoarthritis

INTRODUCTION

Articular cartilage is a specialized connective tissue that covers the ends of bones in synovial joints. Structure of articular cartilage alters between birth and maturity. It shows a decline in cellularity, a slight reduction in water content and a fall in rate of protein synthesis per cell.¹

Osteoarthritis (OA) is a common disabling condition, characterized by degeneration of articular cartilage accompanied by bony changes. Radiographic changes

include joint space narrowing, osteophytes, cysts and subchondral sclerosis. Although OA is a common problem in elderly, it is not an inevitable feature of ageing.² About 80-90% of individuals of both sexes have radiographic evidence of OA by the time they reach an age of 65. But not all of them have symptoms like pain and decreased joint motion. The primary changes in OA are fibrillation and loss of articular cartilage accompanied by thickening

and remodeling of the subchondral bone.³ It is unclear however, whether these changes in cartilage morphology are different from normal ageing in the absence of cartilage disease.⁴

OA has long been thought of as a condition affecting the extracellular matrix but the chondrocytes also play a pivotal role in the catabolic and anabolic processes that drive the degenerative process.⁵ The present study was conducted to find out whether the osteoarthritic changes in chondrocytes of human articular cartilage are similar to ageing process or not. The ultrastructure of chondrocytes of osteoarthritic femoral articular cartilage was compared with those of normal adult cartilage to clarify the differences between osteoarthritic and age-induced changes.

METHODS

Thirteen osteoarthritic cartilage specimens were obtained from patients with primary OA (52-80years) undergoing total knee replacement in the department of Orthopaedics, Postgraduate Institute of Medical Education and Research (PGIMER), Chandigarh from January, 2004 to January, 2008. Clinical data was carefully reviewed to exclude any form of secondary OA and inflammatory joint disease like rheumatoid arthritis. Control cartilage specimens were collected from 9 cadavers of same age group (50-80years) from the department of Anatomy, PGIMER, Chandigarh within 18hrs after death. Individuals suffering from any disease of knee joint like tumor, any deformity, bony enlargement or irregularities such as osteophytes were not included in the control group. Informed consent of the subjects included in the study was obtained and approval was obtained from the institute ethics committee.

Cartilage specimens were obtained from the most prominent area of the medial femoral condyle and cut into small pieces (1x1x1mm) using surgical blade and fixed in 2.5% glutaraldehyde in Sorensen's phosphate buffer at 4°C. The specimens were then processed for conventional electron microscopy and embedded in Epoxy resin. 60-90nm thick ultrathin sections were cut using diamond knife, mounted on copper grids and double stained with uranyl acetate and lead citrate and examined under Transmission electron microscope (Zeiss EM-906).^{6,7}

RESULTS

Control group: The chondrocytes of the control group resembled a typical secretory cell with the cell membrane showing many cytoplasmic processes of variable size extending into the surrounding matrix and a prominent nucleus with chromatin distributed near the nuclear membrane (Fig.1). Chondrocytes had intracytoplasmic lipid droplets of variable electron density. Some of these lipid droplets were closely associated with mitochondria. When viewed under higher magnification, many smooth walled vacuoles, intensely electron dense glycogen deposits, abundant rough endoplasmic reticulum and other cell

organelles were seen within the chondrocytes (Fig.2). Variable amount of rER was seen in the form of scattered short lengths of membrane-pairs. A moderate degree of dilatation of cisternae of rER was seen in some of the cells. Glycogen deposits were seen as scattered particles or as small aggregates. Different types of vesicles and vacuoles were also observed in the region of golgi and as micropinocytotic vesicles near the cell membrane. Those near the golgi had a partial or complete lining membrane and a mainly clear content which sometimes had some stained material. Some chondrocytes had collections of densely packed intracytoplasmic fine filamentous fibres. These fibres were usually perinuclear in situation.

Extracellular matrix: At places the chondrocytes were surrounded by a clear fibre free zone representing the lacuna. The extracellular matrix had abundant membrane bound electron dense lipid droplets. At the junction of zone III and IV small calcium deposits were seen lying in between the collagen fibres (Fig.3).

Osteoarthritic Group: In the osteoarthritic articular cartilage, most of the surface was fibrillated. Degenerating or necrotic chondrocytes were found below these fibrillated areas. Nuclei of these chondrocytes appeared lobulated or indented (Fig.4). Some of these nuclei even had a shrunken crenated contour and a structure less homogenous appearance. Number of apoptotic chondrocytes was also observed. These cells had condensed nuclear material. No organelles could be identified in the cytoplasm and the cells were surrounded by numerous membrane bound bodies containing degenerating cell contents and lipid (Fig.5). Changes were also observed in the chondrocytes below the non-fibrillated area. The rER was very much dilated and had irregular cisternae (Fig.6). Mitochondrial swelling and disorganization of cristae were seen within the cytoplasm. Many double lining membrane-bound vesicles containing cristae like structures were seen. These could be altered and swollen mitochondria. The amount of intracytoplasmic fine filaments in the chondrocytes was also increased (Fig.7). Almost all the cells had abundant intracytoplasmic fine filaments and in such cells there was a reduction in organelle content as they were replaced by fine filaments.

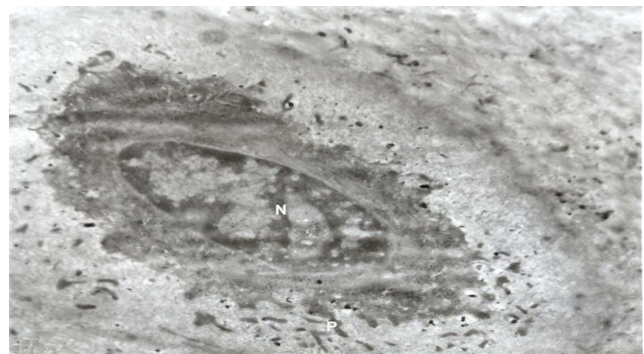

Figure 1. Electronmicrograph of chondrocyte from control group (50year male) showing many cytoplasmic processes (P) and a prominent nucleus (N). ×10000.

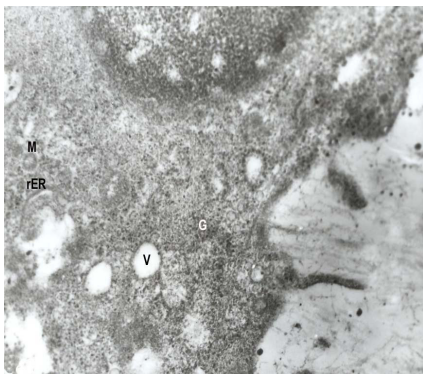


Figure 2. Electronmicrograph of chondrocyte from control group (70year male) showing vacuoles (V), glycogen deposits (G), mitochondria (M) and rough endoplasmic reticulum (rER). $\times 28000$.

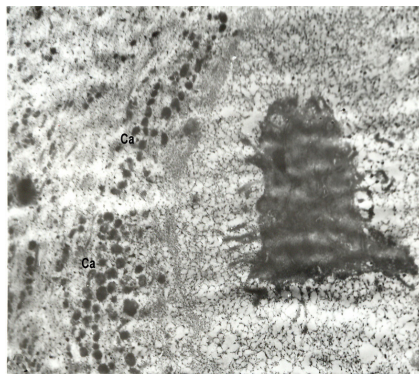


Figure 3. Electronmicrograph of articular cartilage from control group (60year male) showing calcium deposits (Ca). $\times 10000$.

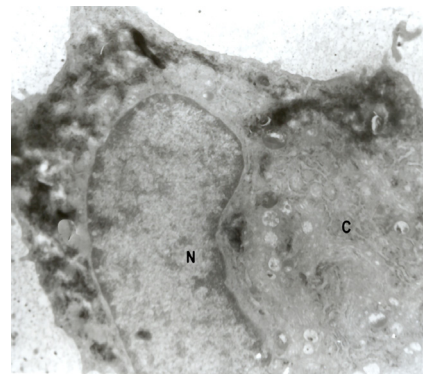


Figure 4. Electronmicrograph of articular cartilage from osteoarthritic group (81year female) showing indented nucleus (N) and cytoplasm (C) with cell organelles. $\times 10000$.

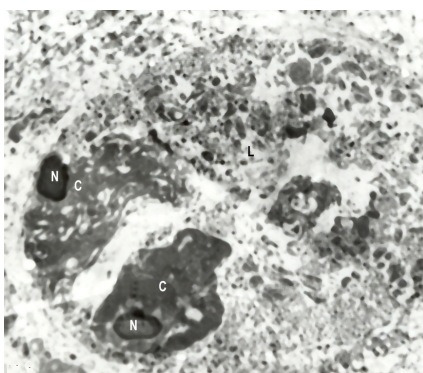


Figure 5. Electronmicrograph of articular cartilage from osteoarthritic group (70year male) showing degenerating chondrocytes-crenated nucleus (N), cytoplasm (C) and lipid deposits (L). $\times 8000$.

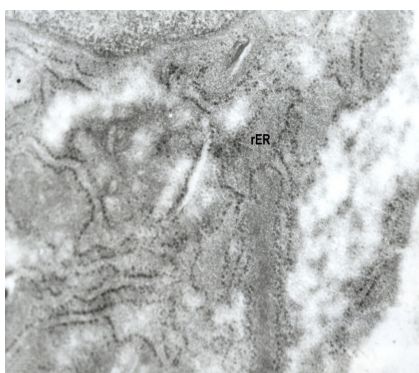


Figure 6. Electronmicrograph of chondrocyte from osteoarthritic group (70year male) showing dilated and irregular rough endoplasmic reticulum (rER). $\times 36000$.

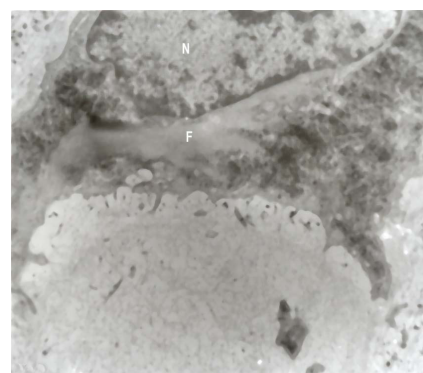


Figure 7. Electronmicrograph of chondrocyte from osteoarthritic group (81year female) showing abundant intracytoplasmic fine filaments (F). $\times 10000$.

Extracellular matrix: Osteoarthritic cartilage had much more extracellular lipid deposits in the matrix. Even the degenerating chondrocytes were surrounded by large deposits of lipid and degenerating cellular contents (Fig.5). At places, calcium deposits were also present in between the bundles of collagen fibres. Coarse collagen fibres were observed in the extracellular matrix.

DISCUSSION

In previous light microscopic studies we observed altered histology, loss of zonation, formation of clusters of chondrocytes and increased levels of matrix components, osteocalcin, osteopontin, osteonectin and alkaline phosphatase in the osteoarthritic articular cartilage.^{8,9} The present study was conducted to determine various differences in the morphology of chondrocytes from ageing and osteoarthritic articular cartilage and to observe whether the ageing process is different from OA or not.

The cell membrane showed many cytoplasmic processes by electron microscopy and was ruffled in appearance in control as well as osteoarthritic group. Sheldon stated that the ruffled cell membrane could be the result of exchange

of vacuoles from the cytoplasm with the matrix.¹⁰ Many smooth walled vacuoles were also observed near the cell membrane in the present study. These may represent the cut sections of cell invaginations or may be derived by fusion of micropinocytotic vesicles or from the golgi and are considered to be concerned with transport and release of materials into the matrix.¹

Intracytoplasmic lipid droplets in the present study were present in both control as well as osteoarthritic articular cartilage. According to Davies et al these lipid droplets are a readily accessible store of material which can be used as a source of energy or chemical building blocks for metabolic activities of the cell.¹¹ Increase in these lipid droplets (osmophilic bodies) in OA could be a sign of degeneration.

The amount of intracytoplasmic fine filaments in the chondrocytes was markedly increased in the osteoarthritic cartilage. In these cells with large fibre deposits there was paucity of organelles and the organelles appeared pushed to the periphery. Several hypothesis have been advanced to explain the accumulation of these filaments which include: excessive protein pool, degeneration of intracellular components and modification of cytoskeleton in OA.¹²⁻¹⁴ Meachin (or Meachim?) and Roy stated that such gross deposits probably indicate a degenerative change.¹⁵

A clear extracellular fibre free area was seen adjacent to some chondrocytes which gave a secretory cell appearance. This relatively clear area has been earlier interpreted as a shrinkage artifact.¹¹ But according to Meachim this narrow zone containing mainly ground substance of low electron density exists adjacent to many chondrocytes and its size and distribution are dependent on the state and functional activity of chondrocytes which appears to be so in the present study as these cells had many cytoplasmic processes and prominent euchromatic nucleus.¹ Sheldon also stated that this area is not an artifact and is the site of polymerization of newly synthesized matrix components as these molecules are easily extracted during the preparative procedures and the maturation of these secretory products takes place in matrix just outside the chondrocytes.¹⁰

Number of apoptotic cells was observed in the osteoarthritic cartilage by electron microscopy in the present study. Kuhn et al and Kurz et al have also stated that apoptotic cell death occurs to a significant extent in the osteoarthritic articular cartilage and also stated that chondrocyte death is the central factor in the initiation of OA.^{16,17} Blanco et al analyzed the presence of apoptotic cells in articular cartilage by using TUNNEL technique but TUNNEL staining is not suitable to distinguish between apoptosis and necrosis as it gives false positive signals.^{18,19} Techniques like DNA laddering and caspase activity for apoptosis detection are suitable for cell culture experiments and tissues with less extracellular matrix, but in cartilage these are insufficient. So, electron microscopy is the more reliable tool for identification and ultrastructural characterization of apoptotic cells in cartilage.²⁰ In the present study the apoptotic cells were clearly identified in the osteoarthritic cartilage by electron microscopy.

Extracellular lipid deposits increased in the osteoarthritic cartilage. Presence of this lipid in the matrix could be because of either the chondrocyte disintegration or the shedding of the cytoplasmic processes of healthy chondrocytes, while Aigner et al stated that extensive cell debris within the lacuna may be a result of technical artifact but did not completely exclude the possibility of the appearance of this cell debris due to cell death.²¹⁻²³ Presence of lipid around healthy cells and long cytoplasmic processes extending into the lipid aggregates in control group suggests that this lipid results from the detachment of the tips of such processes as described by Ghadially et al.²² In the present study multiple extracellular lipid deposits and cell contents were also present around the disintegrating chondrocytes in the osteoarthritic cartilage and appeared to be extending out from the lacuna into the matrix. This suggests that extracellular lipid is also produced by in situ disintegration of chondrocytes.²¹

In the present study, we observed coarser collagen fibres in the extracellular matrix of osteoarthritic articular cartilage. Yamamoto et al also observed thicker collagen fibres in the matrix of articular cartilage of C57 black mice.²⁴ In a previous study, we observed coarse and irregular fibres under the light microscope.⁸ Meachim and Brooke described that new fibrous tissue can form as a part of the remodeling process

in the degenerating articular cartilage.²⁵ But this new tissue is topographically separate from the degenerating tissue and does not contribute to its repair and any such attempt of repair is severely counteracted by the osteoarthritic wear process.

Numerous studies have been conducted to study the cell-matrix interactions to develop therapeutic strategies which can contribute to reversing the damage in joint cartilage.²⁶⁻²⁸ Bock et al, Tesche and Miosge studied the expression of matrix components- decorin, bi-glycan and perlecan by in situ hybridization and immunohistochemistry and observed their up-regulated levels in OA, probably in an effort to compensate for the general proteoglycan loss, characteristic of this disease stage.^{26,27} Koelling et al observed increased levels of collagen type IX in osteoarthritic cartilage and stated that this could be an effort of the degenerating cartilage to protect the remaining matrix from further destruction.²⁸ But articular cartilage is characterized by low intrinsic repair capacity. One major reason is an insufficient recruitment of cells with chondrogenic potential based on the low cell content of cartilage. So a detailed knowledge of structure of chondrocytes in OA and age matched cartilage may help in better understanding of the disease process.

In normal ageing, the structure of articular cartilage was found to be intact and few changes like moderate degree of dilatation of rER, densely packed intracytoplasmic fine filaments and presence of abundant lipid deposits were observed but these are associated with the normal ageing process. Such changes were much more pronounced in the osteoarthritic cartilage of the same age suggesting that osteoarthritic changes are not necessarily caused by ageing only but involve some other mechanisms and factors which need to be further investigated to develop future therapeutic approaches.

In the present study, the structure of the articular cartilage was studied in detail using electron microscope to suggest that the ageing is different from OA. Due to limited number of specimens available, we could not consider the sex differences which could affect the results. More studies assisted by biochemical and radiological techniques are required to further strengthen the idea.

CONCLUSION

The present study was conducted to determine various differences in the morphology of chondrocytes from ageing and osteoarthritic articular cartilage and to observe whether the ageing process is different from OA or not. Ultrastructural findings of the osteoarthritic articular cartilage were much different from the ageing non-osteoarthritic cartilage. Hence, OA should be considered a specific process and not simply an inevitable feature of ageing.

REFERENCES

- Meachim G. Age and osteoarthritic changes in articular cartilage. In: Ghadially FN, Roy S, editors. *Ultrastructure of synovial joints in health and disease*. Butterworths and Co Ltd: London. 1969: 61-82.
- Lanyon P, O'Reilly S, Jones A, Doherty M. Radiographic assessment of symptomatic knee osteoarthritis in the community: definitions and normal joint space. *Ann Rheum Dis*. 1998; 57 (10): 595-601.
- Rosenberg A. Bones, Joint and Soft Tissue Tumors. In: Cotran RS, Kumar V, Collins T editors. *Robbins Pathologic Basis of Disease*. 6th Ed. WB Saunders Co: Philadelphia; 1999, p. 1246-8.
- Hudelmaier M, Glaser C, Hohe J, Englmeier KH, Reiser M, Putz R, et al. Age related changes in the morphology and deformational behaviour of knee joint cartilage. *Arthritis Rheum*. 2001; 44 (11): 2256-61.
- McGlashan SR, Cluett EC, Jensen CG, Poole CA. Primary cilia in osteoarthritic chondrocytes: from chondrons to clusters. *Dev Dynamics*. 2008; 237: 2013-20.
- Watson ML. Staining of tissue sections for electron microscopy with heavy metals. II Application of solution containing lead and barium. *J Biophys Biochem Cytol*. 1958; 4: 727-30.
- Reynolds ES. The use of lead citrate at high pH as an electron opaque stain in electron microscopy. *J Cell Biol*. 1963; 17: 208-12.
- Goyal N, Gupta M, Joshi K, Nagi ON. Osteoarthritic femoral articular cartilage of knee joint in man. *Nepal Med Coll J* 2006; 8: 88-92.
- Goyal N, Gupta M, Joshi K, Nagi ON. Immunohistochemical Analysis of Ageing and Osteoarthritic Articular Cartilage. *J Mol Histol*. 2010; 41: 193-7.
- Sheldon H. Transmission electron microscopy of cartilage. In Hall BK, editors. *Cartilage*. Vol.1. Academic Press: New York;1983.p.87-104.
- Davies DV, Barnett CH, Cochrane W, Palfrey AJ. Electron microscopy of articular cartilage in the young adult rabbit. *Ann Rheum Dis*.1962; 21: 11.
- Kanie R. Ultrastructural findings on the aging of articular cartilage. *J Clin Exp Med*. 1986; 136: 108-11.
- Kouri JB, Arguello C, Luna J, Mena R. Use of microscopical techniques in the study of human chondrocytes from osteoarthritic cartilage: an overview. *Microsc Res Tech*. 1998; 40: 22-36.
- Kouri JB, Aguilera JM, Reyes J, Lozoya KA, Gonzalez S. Apoptotic chondrocytes from osteoarthritic human articular cartilage and abnormal calcification of subchondral bone. *J Rheum*. 2000; 27: 1005-19.
- Meachim G, Roy S. Intracytoplasmic fine filaments in the cell of adult human articular cartilage. *Ann Rheum Dis*. 1967; 26:50.
- Kuhn K, D'Lima DD, Hashimoto S, Lotz M. Cell death in cartilage. *Osteoarthritis Cartilage*. 2004; 12: 1-16.
- Kurz B, Lemke AK, Fay J, Pufe T, Grodzinsky, Schunke M. Pathomechanism of cartilage destruction by mechanical injury. *Ann Anat*. 2005; 187: 473-85.
- Blanco FJ, Guitian R, Vazquez-Martul E, Toro FJ, Galdo F. Osteoarthritis chondrocytes die by apoptosis. *Arthritis Rheum*. 1998; 41 (2): 284-9.
- Aigner T, Hemmel M, Neureiter D, Gebhard PM, Zeiler G, Kirchner T, et al. Apoptotic cell death is not a widespread phenomenon in normal aging and osteoarthritic human articular knee cartilage. *Arthritis Rheum*. 2001; 44 (6): 1304-12.
- Patwari P, Gaschen V, James IE, Berger E, Blake SM, Lark MW, et al. Ultrastructural quantification of cell death after injurious compression of bovine calf articular cartilage. *Osteoarthritis Cartilage*. 2004; 12 (3): 245-52.
- Barnett CH, Cochrane W, Palfrey AJ. Age changes in articular cartilage of rabbits. *Ann Rheum Dis* 1963; 22:389.
- Ghadially FN, Roy S, Meachim G, Collins DH. Extra-cellular lipid in the matrix of human articular cartilage. *Ann Rheum Dis* 1965; 24:136.
- Aigner T, Gluckert K, Von der mark K. Activation of fibrillar collagen synthesis and phenotypic modulation of chondrocytes in early human osteoarthritic cartilage lesions. *Osteoarthritis Cartilage*. 1997; 5: 183-9.
- Yamamoto K, Shishido T, Masaoka T, Imakiire A. Morphological studies on the ageing and osteoarthritis of the articular cartilage in C57 black mice. *J Orthop Surg*. 2005; 13: 8-18.
- Meachim G, Brooke G. The pathology of osteoarthritis. In Moskowitz RW, Howell DS, Goldberg VM, Mankin HJ, editors. *Osteoarthritis: Diagnosis and management*. WB Saunders Co: Philadelphia; 1984.p. 29-42.
- Bock HC, Michaeli P, Bode C, Schultz W, Kresse H, Herken R et.al. The small proteoglycans decorin and biglycan in human articular cartilage of late-stage osteoarthritis. *Osteoarthritis Cartilage*. 2001; 9: 654-63.
- Tesche F, Miosge N. Perlecan in late stages of osteoarthritis of the human knee joint. *Osteoarthritis Cartilage*. 2004; 12: 852-62.
- Koelling S, Kruegel J, Klinger M, Schultz W, Miosge N. Collagen IX in weight-bearing areas of human articular cartilage in late stages of osteoarthritis. *Arch Orthop Trauma Surg*. 2008; 128: 1453-9.